

# Mecklenburg County M E Office

3440 Reno Avenue, Charlotte, NC 28216

Telephone 7043362005

Fax 7043368353

## REPORT OF AUTOPSY EXAMINATION

### DECEDENT

**Document Identifier** B201603608

**Autopsy Type** ME Autopsy

**Name** Jordyn Ann Dumont

**Age** 3 yrs

**Race** White

**Sex** F

### AUTHORIZATION

**Authorized By** Carol V. Pinkard RN

**Received From** Gaston

### ENVIRONMENT

**Date of Exam** 08/17/2016

**Time of Exam** 13:00PM

**Autopsy Facility** Mecklenburg County M E Office **Persons Present** Ms. Linnelle Banks

### CERTIFICATION

#### Cause of Death

Blunt Force Injuries due to Assault

**The facts stated herein are correct to the best of my knowledge and belief.**

#### Digitally signed by

Jonathan Privette MD 20 October 2016 11:44

### DIAGNOSES

Blunt force injuries

Abrasion and contusions across the body

Subgaleal hemorrhages

Pancreas laceration

Mesentery laceration with retroperitoneal hemorrhage and hemoperitoneum

### IDENTIFICATION

#### Body Identified By

Papers/ID Tag

### EXTERNAL DESCRIPTION

**Length** 40 inches

**Weight** 32 pounds

**Body Condition** Intact

**Rigor** None

**Livor** Posterior, fixed

**Hair** Brown, with a normal pattern of distribution

**Eyes** Cloudy

**Teeth** Natural, in fair repair

Received is the body of a well-developed, well-nourished female child appearing compatible with the reported age. The body is clad in shirt, shorts, underwear and socks. Nothing accompanies the body. There are no readily identifiable marks or scars. There is no evidence of medical intervention.

### INJURIES

#### External Examination

There is dirt across the body. Decomposition changes are manifested by a green discoloration of the abdomen. The

body is received with the shorts and underwear partially pulled down over the upper thighs. The underwear are fluid stained.

There is pressure blanching at the left forehead. There is postmortem drying at the nose. At the posterior left scalp is an area of contusion and soft tissue swelling covering an area of 6" x 5". There is a 1/2" abrasion at the posterior aspect of the right helix. There are abrasions at the upper and lower lips that range in size from 1/8" to 1/4". There is 1/2" contusion at the chin. There is a linear abrasion at the left chin.

On the anterior chest and abdomen at least ten contusions are identified. These range in size from 1/4" to 1 1/2". There is a 1/4" abrasion lateral to the right nipple and linear abrasion at the left lower quadrant of the abdomen.

At least six contusions involve the right arm and hand. These range in size from 1/4" to 3/4".

At least fourteen contusions involve the left arm and hand. These range in size from 1/4" to 1 3/4".

There is a linear abrasion on the right back. At least four contusions are identified on the posterior abdomen and buttocks. These range in size from 1/4" to 1".

There is healing linear abrasion on the right thigh.

There are at least eleven contusions identified on the right leg and foot including involvement of the plantar surface of the right foot. These range in size from 1/4" to 1 3/4".

At least fifteen contusions are identified on the left leg and foot including the plantar surface of the left foot. These range in size from 1/4" to 3". There is an abrasion on the top of the left foot.

There is a 1 1/2" ecchymosis around the anus with relative sparing at the 12 o'clock and 6 o'clock position. This may represent postmortem change. Definitive abrasion and laceration is not identified.

### **Internal Examination**

Reflection of the scalp reveals an area of subgaleal hemorrhage overlying the right frontal/parietal region of the skull that extends to 2 1/2". There is an area of subgaleal hemorrhage overlying the left temporal/occipital region extending to 5". There is thick overlying scalp hematoma at this location.

Reflection of the skin at the anterior chest and abdomen reveals numerous soft tissue ecchymoses. There is extensive soft tissue hemorrhage at the bilateral inguinal region.

Upon opening the body cavities, liquid blood spills from the abdominal cavity. Approximately 300 cc of liquid blood is collected. A 2.5" mesenteric laceration is identified at the small bowel and right colon mesentery. There is extensive retroperitoneal hemorrhage predominantly at the right. There is a laceration of the pancreas at mid body.

### **DISPOSITION OF PERSONAL EFFECTS AND EVIDENCE**

#### **The following items are released with the body**

None

#### **The following items are preserved as evidence**

The following items are released to JD Costner of the Gaston County Police on September 29, 2016:

CLOTHING  
SEXUAL ASSAULT KIT  
FINGERNAIL SWABS  
TRACE SHEETS

### **PROCEDURES**

#### **Radiographs**

Whole body radiographs do not reveal any osseous abnormalities.

## **INTERNAL EXAMINATION**

### **Body Cavities**

The bilateral pleural cavities are free of significant fluid and adhesions. The organs are in their normal anatomic positions.

### **Cardiovascular System**

**Heart Weight** 60 grams

The pericardial sac is free of significant fluid and adhesions. The coronary arteries arise normally, follow the usual distribution and are widely patent. The chambers and valves bear the usual size-position relationships and are unremarkable. The myocardium shows no evidence of acute infarction, scarring or focal lesions. The aorta and its major branches are intact without significant atherosclerosis.

### **Respiratory System**

**Right Lung Weight** 80 grams

**Left Lung Weight** 70 grams

Examination of the soft tissues of the neck including the strap muscles and large vessels reveals no abnormalities. The hyoid bone and laryngeal cartilages are intact. The larynx is clear. The lingual mucosa is intact; the underlying musculature is devoid of hemorrhage. The upper and lower airways are free of debris and foreign material. The lungs are normally formed. The parenchyma of both lungs shows moderate congestion without obvious consolidation or focal lesions. The pulmonary arteries are free of thrombi or emboli.

### **Gastrointestinal System**

Except as previously noted, grossly unremarkable. The stomach contains 20 ml of yellow/white partially digested food.

### **Liver**

**Liver Weight** 360 grams

The capsule is intact and the parenchyma is unremarkable. The gallbladder contains bile. The extrahepatic biliary tree is patent.

### **Spleen**

**Spleen Weight** 30 grams

The spleen is normally formed; no focal lesions are present.

### **Pancreas**

Except as previously noted, grossly unremarkable.

### **Urinary**

**Right Kidney Weight** 30 grams

**Left Kidney Weight** 30 grams

The kidneys are of normal size and shape. The capsules strip with ease from the underlying smooth cortical surfaces. The renal architecture is intact without focal lesions. The bladder is empty.

### **Reproductive**

Grossly unremarkable.

### **Endocrine**

The thyroid gland and bilateral adrenal glands are grossly unremarkable.

### **Neurologic**

**Brain Weight** 1241 grams

Reflection of the scalp reveals the previously described injuries. There are no skull fractures identified. The leptomeninges are thin, delicate and congested. The cerebral hemispheres are unremarkable. The vasculature at the base of the brain is intact without significant atherosclerosis. Coronal sections reveal normal architecture without focal lesions.

### **Skin**

Except as previously noted, grossly unremarkable.

### **Immunologic System**

Grossly unremarkable.

**Musculoskeletal System**

Except as previously noted, grossly unremarkable.

**MICROSCOPIC EXAMINATION****Microscopic Comment**

Histologic examination is not performed.

**SUMMARY AND INTERPRETATION**

The decedent was a 3-year-old child who was initially reported missing from her home and was later found outdoors covered with vegetation.

Autopsy examination reveals numerous blunt force injuries.

Toxicology studies are non-contributory.

Based on the history and autopsy findings, it is my opinion that the cause of death in this case is blunt force injuries.

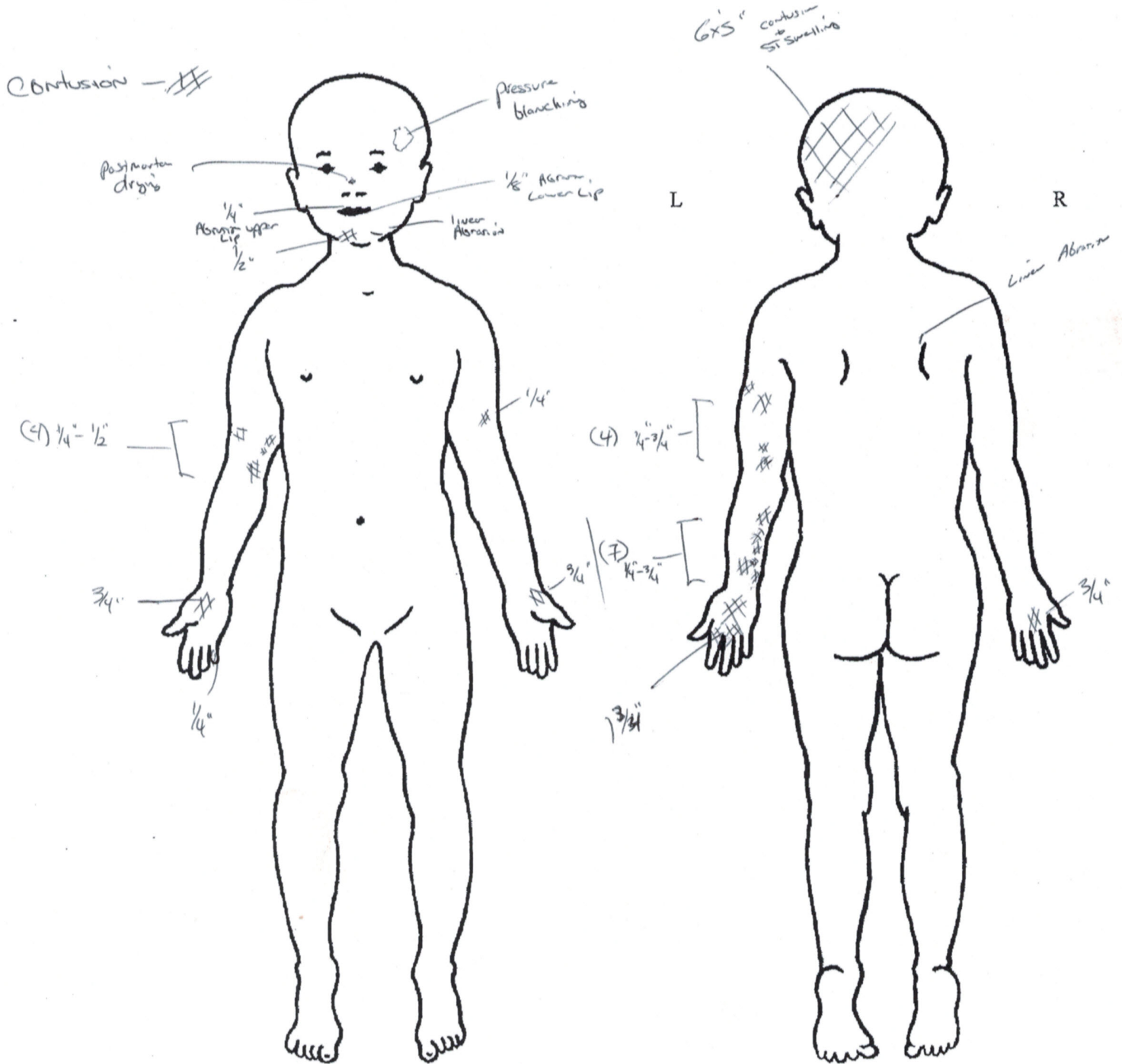
**DIAGRAMS**

1. CHILD autopsy diagram
2. BODY DIAGRAM: INFANT (FRONT/BACK, L/R)

State of North Carolina  
Mecklenburg County Medical Examiner's Office  
Charlotte, North Carolina 28216

Name of Decedent: JORDYN ANN DUMONT  
B#: 16-3608  
Examined by: \_\_\_\_\_ Date: \_\_\_\_\_

IDENTIFICATION: \_\_\_ ID checked



Name of Decedent: JORDYN DEMONT  
B#: 16-3608  
Examined by: [Signature] Date: \_\_\_\_\_

IDENTIFICATION: \_\_\_ ID checked

*Dirt across body*

*Contusion - ###*

